

Mid-term results following Unicondylar replacement and ACL reconstruction in knee with functional instability and osteoarthritis. A single center follow-up study.

S. Schneider, R. Hofmann, A. Ilg, C. Lütten, J. Holz

Purpose:

Sports activities require a functioning anterior cruciate ligament, which ensures both anterior translation and rotation stability of the knee joint.¹ A healthy meniscus reacts to anteroposterior movements of the femur towards the tibia and to axial rotation. When flexing, the meniscus changes its position by up to 11 mm, thereby also changing its shape to adapt to the polyradial shape of the femoral condyle, creating the greatest possible contact area.

These properties of the knee joint can be preserved or restored when patients with unicondylar arthritis in the presence of an anterior cruciate ligament (ACL) rupture are treated with a combination of mobile bearing resurfacing unicondylar knee replacement and an arthroscopic ACL reconstruction in a one or two-step-procedure.^{2,3} The best way to achieve anatomical ACL graft positioning without compromising the bone canal position in the tibia to avoid a graft impingement or damage due to the metal tibia base is to use an *all inside socket drilling technique*. The intention of this follow-up study was to evaluate the mid-term clinical, radiological and functional outcome of this procedure.

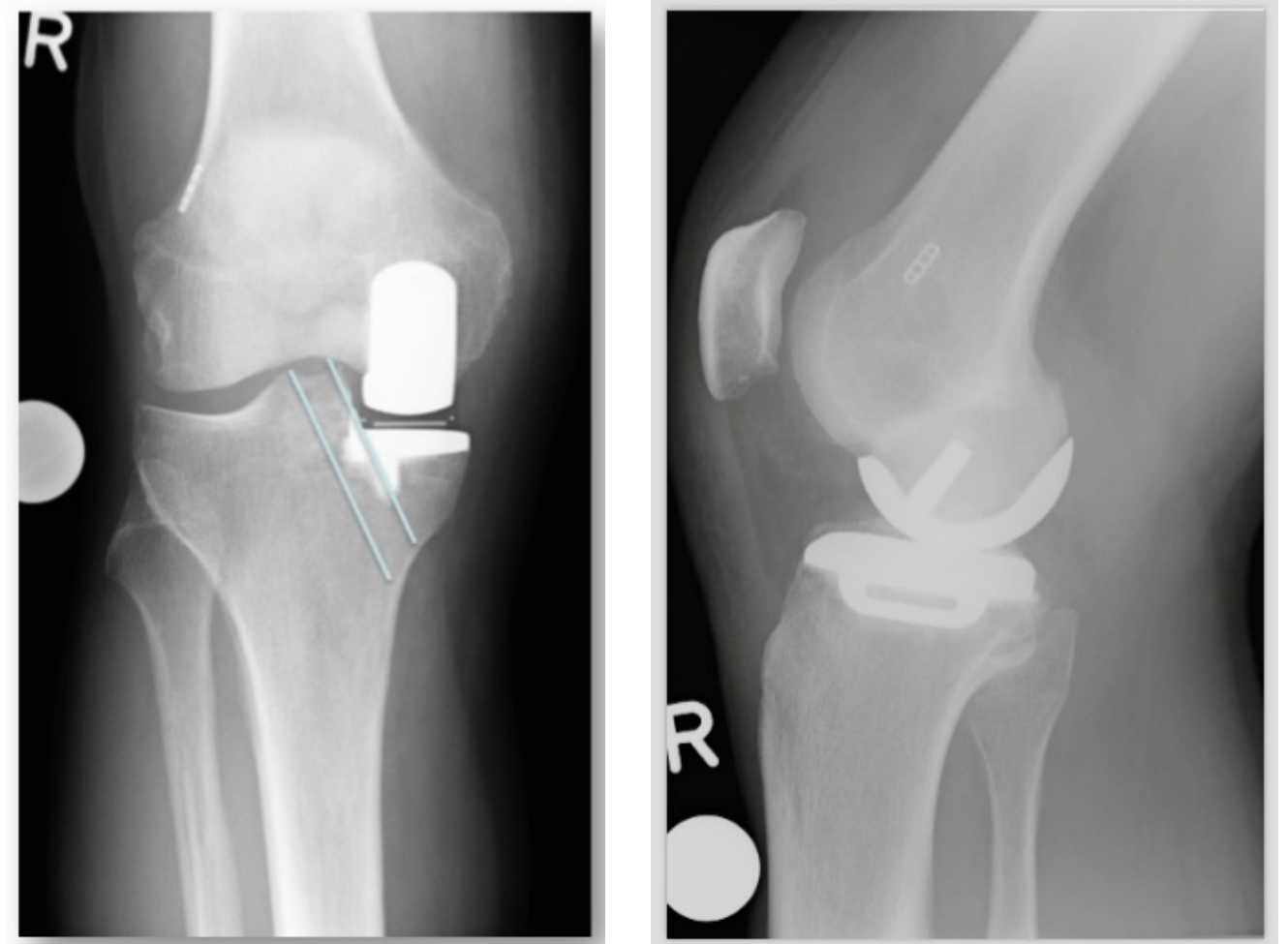


Fig. 1+2: post operative x-ray after ACL Reconstruction and Unicondylar Knee Replacement

Methods:

22 patients were followed up for 2 years (mean). The average age of the 15 men and 7 women was 57 years. All patients were treated by combined uni-compartmental knee arthroplasty and anterior cruciate ligament reconstruction. 5 of them received a reconstruction of the ACL and the unicondylar replacement in one step. 17 patients underwent a primary reconstruction of the ACL. In case the patient still complained about pain in the affected compartment, a unicondylar replacement was conducted as a second step.

Results:

OCH patients treated with this combination of *unicompartmental knee arthroplasty (UKA)* and *anterior cruciate ligament (ACL)* showed a substantial improvement regarding their potential to live out their daily and sport activities. There were no significant differences between genders or the number of surgeries or time past since the last surgery. The procedure is shown to be long-lastingly effective. No revision surgery was required and no radiolucent lines were observed on the radiographs at the time of follow-up.

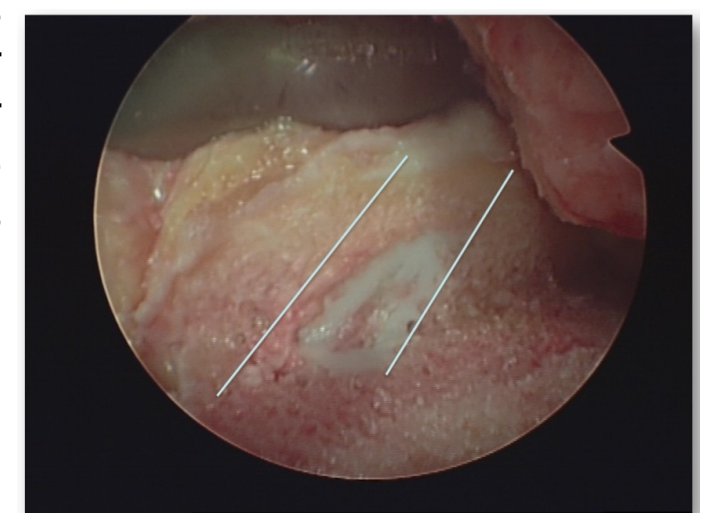


Fig. 3: Positioning of the ACL

Data collection	Score	Post-operative	
		Mean (SD)	Median
Subjects: n=22 (15m & 7f)	VAS	1,7 (1,6)	1,05
Ø Age (SD) 57 (6,8) years	VR-12 PCS	43,53 (8,7)	42,27
Ø last Follow-up (SD) 2 (1,8) years	VR-12 MCS	55,29 (9,1)	56,7
	KOOS	76,54 (16,1)	78,9
	FJS	18,24 (11,2)	18
	EQ-5D	6,81 (2,1)	7
	Tegner	4,3 (1,4)	4,5
	UCLA	5,5 (1,7)	6

Table 1: Data collection with results postoperatively

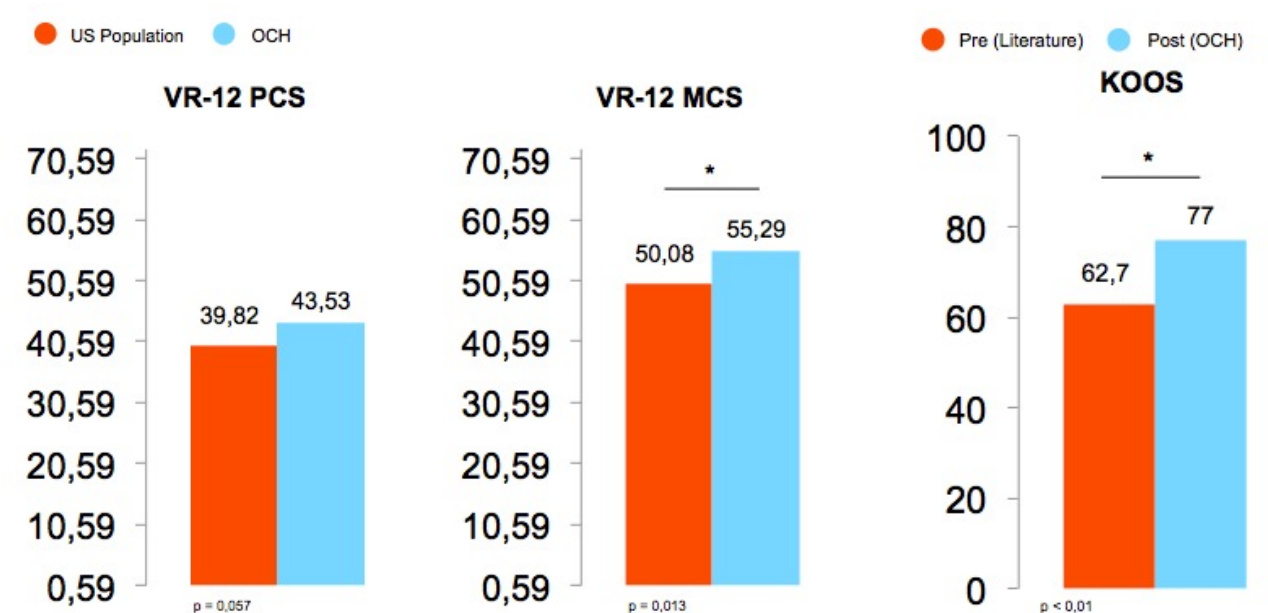


Fig. 4: Results VR-12 PCS and MCS, KOOS pre- and postoperatively

Conclusion:

The midterm clinical data have shown that combined surgery of UKA and ACL reconstruction has satisfactory results. The restored knee stability seems to ensure the success of this treatment. OCH Patients showed an improvement in activity levels.

Literature: 1. Citak M, Bosscher MRF, Citak M, Musahl V, Pearle AD, Suero EM. Anterior cruciate ligament reconstruction after unicompartmental knee arthroplasty. *Knee Surg Sports Traumatol Arthrosc.* 2011;19(10):1683-1688. doi:10.1007/s00167-011-1449-5. 2. Tinius M, Hepp P, Becker R. Combined unicompartmental knee arthroplasty and anterior cruciate ligament reconstruction. *Knee Surg Sports Traumatol Arthrosc.* 2012;20(1):81-87. doi:10.1007/s00167-011-1528-7. 3. Krishnan SR, Randle R. ACL reconstruction with unicondylar replacement in knee with functional instability and osteoarthritis. *J Orthop Surg.* 2009;4(1):43. doi:10.1186/1749-799X-4-43.